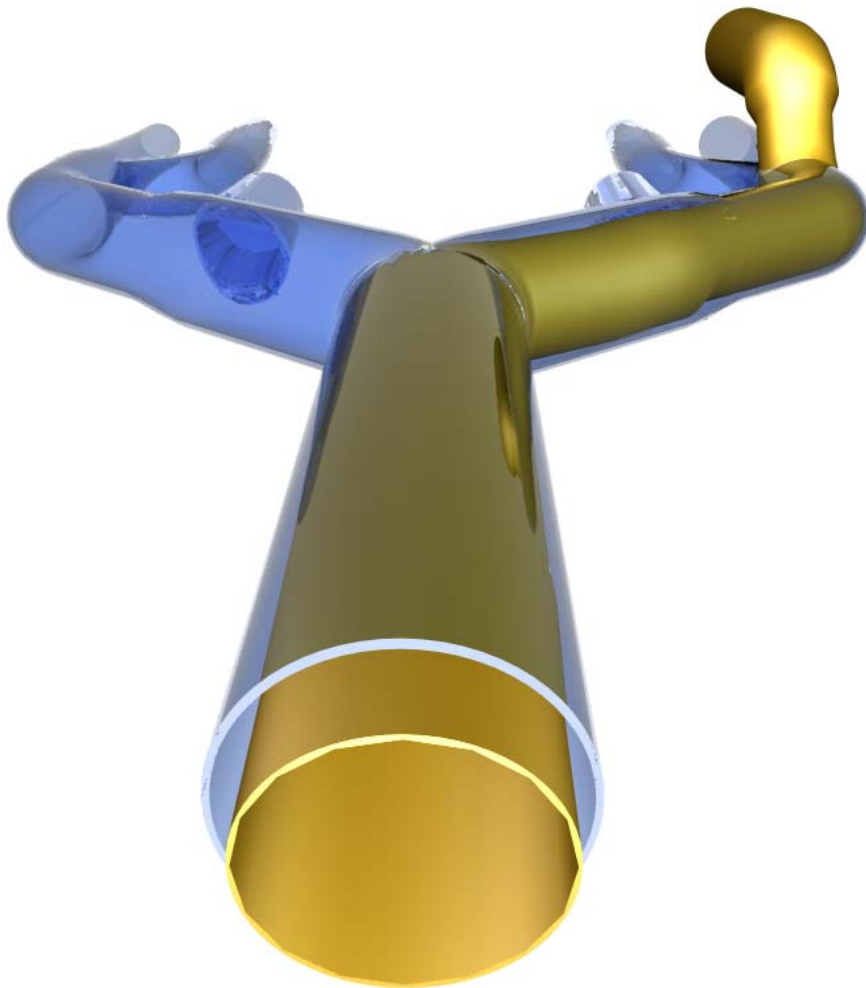


How to do it by smart canula®

Cannulation



A detailed description of smart venous femoral cannulation for optimized venous drainage without augmentation

Optimized venous cannulation with the self expanding smart canula®

Less invasive open heart surgery

Small access open heart surgery (1, 2) has triggered the development of new technologies for efficient remote arterial and venous cannulation in order to avoid partial obturation of the small access to the surgical field. As a matter of fact, the incision required for accessing the heart can be kept smaller, if less instruments are competing for space. Various approaches have been investigated for this purpose in the past. This includes guide-wire compatible cannulas which can be inserted through a small cut-down or in percutaneous fashion in a remote area. However, the main limitation of remote venous cannulation with traditional guide-wire compatible cannulas is inadequate flow. This is due to the fact, that the access vessel, i.e. the femoral vein, has by definition a much smaller diameter as compared to the two venae cava at the level of the right atrium (fig 1). Hence, a centrifugal pump (Biomedicus pump) or vacuum assistance are necessary for augmentation of venous return (2-4). Unfortunately, these adjuncts do usually not allow for full flow (5) and on top of inadequate life support, a significant amount of blood stays within the heart. This is due to the traditional design of long, rectilinear percutaneous cannulas with the access vessel diameter as main limiting factor with regard to cannula size. Even extreme negative pressure will not increase venous drainage.

As a matter of fact, excessive augmentation of venous drainage with vacuum or centrifugal pump assistance, increases the risk of collapsing the venous compartment (6), with consecutive complete shut down of venous drainage.



Fig. 1 Schematic view of the inferior vena cava (typically > 20 mm in diameter), its afferent iliac, as well as femoral vessels (typically approximately 8 mm in diameter)




Fig. 2 Schematic view of the "collapsed insertion and expansion in situ principle": a collapsed smart canula® (left) and an expanded smart canula® (right). In this example, partial expansion occurred over a short distance simulating a small access vessel.

Possibilities for improved venous drainage

Self-expanding smart cannulas based on the smart canula® principle, i. e. “collapsed cannula insertion and expansion in situ within the target vessel” (fig. 2) have been shown to solve this problem. The superior performance of smart cannulation is based on its ability to take advantage of the human anatomy, which by nature increases the diameter of the main veins in vicinity to the heart (fig. 1). In adults, the femoral veins typically measure 8-9mm in diameter, whereas the common iliac veins have diameters of 10mm and more, and the inferior vena cava may reach diameters in excess of 20mm. Hence, a venous cannula that can be inserted from the groin into the venous system with a relatively small diameter, which reaches larger (iliac and caval) diameters within the body (fig. 3) allows for a significant reduction of the narrowed intra-cannular blood path. In accordance to Bernoulli’s law, a shorter restriction results in increased flow as demonstrated by computational fluid dynamics (CFD: 7), increased flow in bench tests (8), and in the experimental setting (9). For the clinical setting, it has been shown, that full venous drainage can be achieved by gravity drainage alone with trans-femoral smart cannulation of the right atrium under echocardiographic guidance (6, 10).

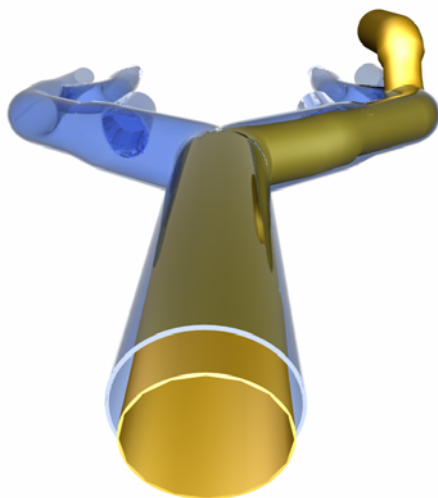


Fig. 3 A smart canula® expanded in situ, i. e. the inferior vena cava. It becomes clear, that the majority of the intravenous blood path towards the pump-oxygenator is unrestricted.

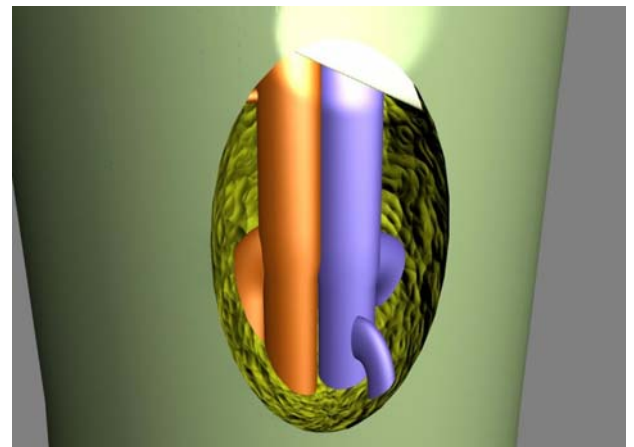


Fig. 4 Right groin prepared for femoral cannulation with its most important landmark: the inguinal ligament (ligamentum inguinale), which runs between the anterior superior iliac spine (spina iliaca anterior superior) and the pubic tuberculum (tuberculum pubicum).

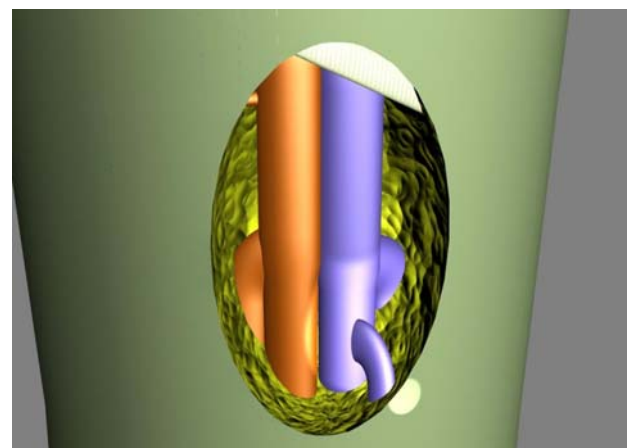


Fig. 5 The origin of the great saphenous vein (vena saphena magna) and its branches is the distal landmark in open access venous femoral cannulation

Practically, self-expanding cannulas are used in similar fashion as percutaneous cannulas, i.e. in open, semi-open or percutaneously. The principal landmark is the inguinal ligament (ligamentum inguinale) which extends between the anterior superior iliac spine (spina iliaca anterior superior) and the pubic tuberculum (tuberculum pubicum: fig. 4). Other land marks include the great saphenous vein (vena saphena magna: fig. 5), and the deep femoral vein (vena femoralis profunda: fig. 6). If an open or a

semi-open cannulation technique is used, a vessel loop can be helpful (fig.7) for single handed control of the common femoral vein prior and during cannulation as well as for and after decannulation. The common femoral vein (vena femoralis communis) is punctured with a hollow needle in the middle between the inguinal ligament (ligamentum inguinale) and the deep femoral vein (vena femoralis profunda) (fig. 8). Once, proper backflow (low pressure, desaturated venous blood: fig. 9) is obtained, a J type guide wire is introduced through the hollow needle (fig. 10) into the common femoral vein, the iliac vein and the caval axis.




Fig. 6 Care is taken to avoid obstruction of the deep femoral vein (vena femoralis profunda) during the perfusion period in order to maintain collateral venous drainage

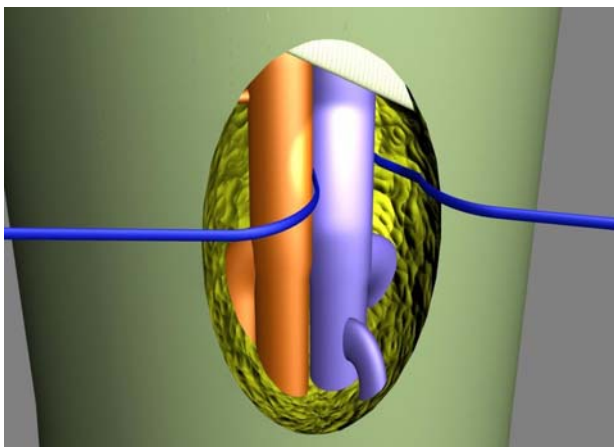


Fig. 7 A vessel loop is helpful for single handed control of the common femoral vein. Combined with a snare it can later be tied to the cannula body for fixation.

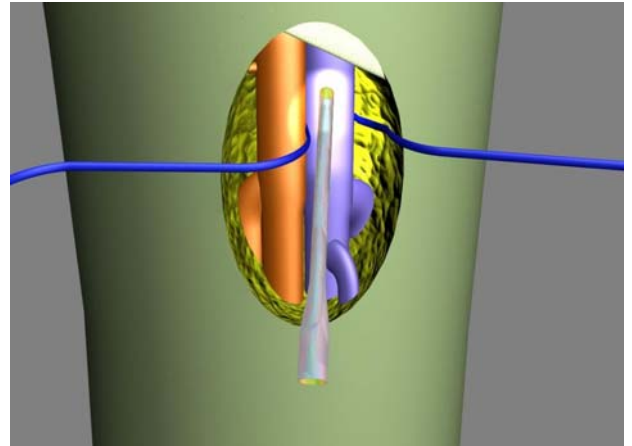


Fig. 8 The optimal puncture site is in between the inguinal ligament (ligamentum inguinale) and the deep femoral vein (vena femoralis profunda) (too caudal puncture may later lead to interference with the deep femoral vein (vena femoralis profunda), to proximal may induce difficulties for control of bleeding after decannulation)

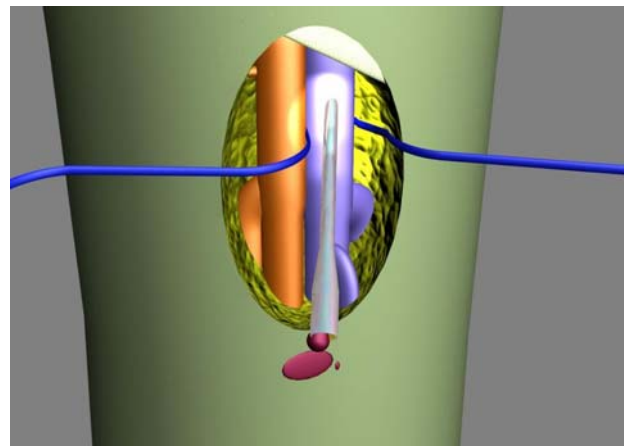


Fig. 9 Relatively low blood pressure (droplets only) and low oxygen saturation (dark) are typical for a venous puncture

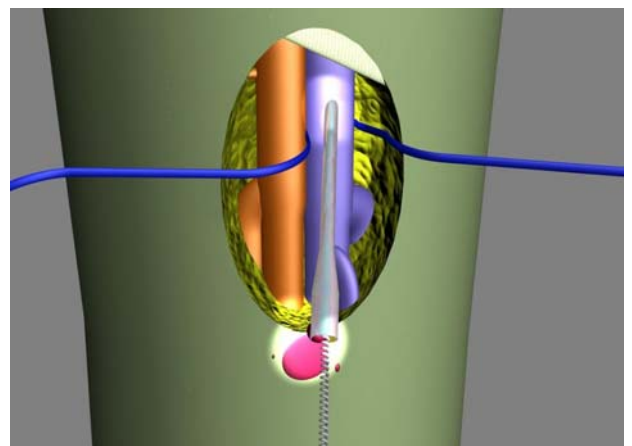


Fig. 10 A J-type guide wire is fed through the hollow needle. The guide wire should pass without resistance until it can be detected in the superior vena cava by TEE or other suitable means

Two self-expanding smart canula® are shown in figure 11. One is stretched over a mandrel (collapsed state: top) and one has expanded after removal of the guide-wire and the mandrel: bottom). A guide wire with a large J (7.5 mm radius) is preferred for femoral cannulation of the right atrium and the superior vena cava. The relatively large J helps for advancing the guide wire within the vena cava and to avoid collateral branches like e. g. a renal vein. For safe operation, it is important that the guide wire can be advanced without resistance and that its final position is checked with suitable means, prior to insertion of the smart canula® (fig. 12). Hence, for trans-femoral right atrial smart cannulation, the guide wire tip should be positioned within the superior vena cava. In similar fashion, the right position of the smart canula® tip can be identified with TEE. Figure 13 shows the final configuration of the expanded smart canula® after removal of both, first the guide wire and second, the mandrel. Again, the effective expansion of the smart canula® can be visualized by TEE (fig. 14). A snare passed over the vessel loop or an additional string positioned around the cannulated vein can be tied to the body of the smart canula® for fixation.

In case of true percutaneous cannulation, an appropriate skin incision and stepwise dilatation (dilators over the wire) up to the diameter of the common femoral vein (in adult patients typically 24F) is necessary prior to insertion of the smart canula® stretched over the corresponding guide wire. For secure fixation, a skin suture and/or tape is used.




Fig. 11 Two self-expanding smart canula® in collapsed (stretched by a guide wire compatible mandrel: top) and expanded shape (after removal of the guide wire and the mandrel: bottom) respectively

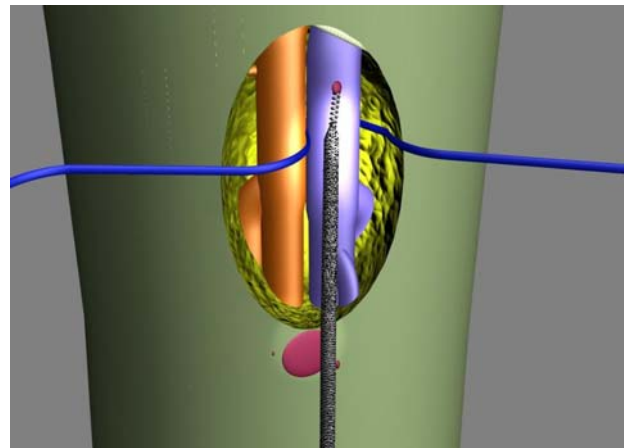


Fig. 12 Schematic view of a collapsed smart canula®, which is inserted over a guide wire into the common femoral vein. Note that the guide wire tip has been previously located in the superior vena cava

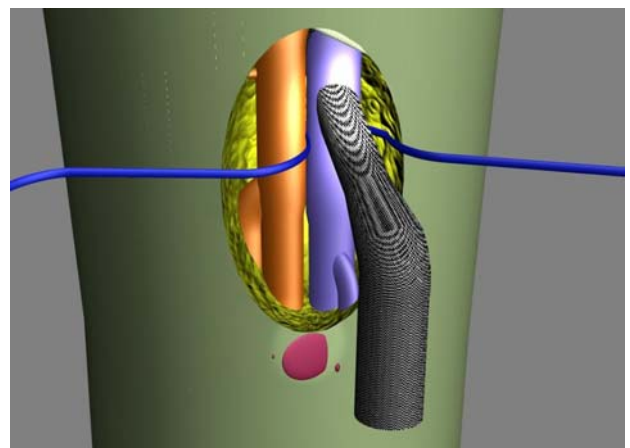


Fig. 13 Schematic view of the expanded smart canula® after removal of the guide wire and the mandrel (note: the guide wire has to be removed prior to the mandrel in order to prevent cannula tip dislocation)

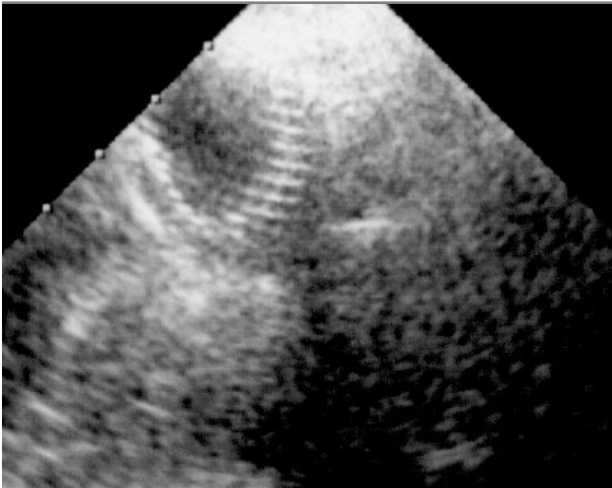


Fig. 14 Transesophageal echocardiography showing the expanded smart canula® within the superior vena cava (trans-femoral access) after withdrawal of the guide wire and the mandrel (allows for self-expansion of the cannula)

Optimized smart venous cannulation for intra-vena-caval procedures

Surgery within the inferior vena cava, e.g. at the level of the hepatic veins, can be difficult for both, the surgical and the perfusion side. As a matter of fact, venous drainage from an open vena cava with traditional femoral cannulation is quite delicate, because the orifices of traditional designs are at their tip, and therefore very close to the surgical field. A permanent struggle between a flooded field versus airlock results, and can make the surgical procedure difficult. In contrast smart cannulation using self expanding cannulae with an open wall design (fig. 11 bottom: the cannula body keeps the vessel wall apart and the vein provides the

seal), allows for drainage of the venous blood from the groin, and significantly reduces the risk of airlocks with only minimal restriction of venous drainage. The technology described makes surgery possible with open right atrium in the absence of a snare around the inferior vena cava. Typical applications for this approach are resections of intra-vena-caval tumours (e.g. renal tumours with extension into the vena cava), hepato-atrial anastomoses (e. g. for Budd-Chiari syndrome:12), and much more frequently, cavo-pulmonary connections (Fontan completion for univentricular heart, tricuspid atresia etc: 12).

Optimized smart venous cannulation for other indications

Optimized smart venous cannulation based on modern cannula designs that allow for large intra-vascular cannula diameters despite a small access orifice is not only helpful in less invasive open heart surgery, but also in difficult redo procedures (e.g. in patients with extra-cardiac conduits incorporated in the sternum), heart transplantation in assist device dependant patients, as well as emergency procedures under critical conditions, where remote cannulation allowing for full flow can be realized with local anesthesia.

Furthermore, it has been demonstrated that smart cannulation of the right atrium through the ipsi-lateral jugular vein or the ipsi-lateral subclavian vein also allows for full drainage without centrifugal pump augmentation, vacuum assistance or other technical artifices. These latter applications are also helpful in patients with so called "crowded groins", but may require stiffer guide wires and proper exchange catheters in order to achieve proper smart canula® tip positioning in the inferior vena cava.

Literature

- 1) von Segesser LK, Westaby S, Pomar J, Loisanche D, Groscurth P, Turina M. Less invasive aortic valve surgery: rationale and technique. *Eur J Cardiothorac Surg* 1999; 15: 781-785
- 2) Bonatti J, Schachner T, Bonaros N, Laufer G. A new exposure technique for the circumflex coronary artery system in robotic totally endoscopic coronary artery bypass grafting. *Interactive CardioVasc Thorac Surg* 2006; 5: 279-281
- 3) Tevaerai HT, Mueller XM, Jegger D, Ruchat P, von Segesser LK. Venous drainage with a single peripheral bicaval cannula for less invasive atrial septal defect repair. *Ann Thorac Surg* 2001; 72: 1772-3
- 4) Jegger D, Tevaearai HT, Horisberger J, Mueller XM, Boone Y, Pierrel N, Seigneul I, von Segesser LK. Augmented venous return for minimally invasive open heart surgery with selective caval cannulation. *Eur J Cardiothorac. Surg* 1999; 16: 312-316.
- 5) von Segesser LK. Cardiopulmonary support and extracorporeal membrane oxygenation for cardiac assist. *Ann Thorac Surg* 1999; 68: 677
- 6) von Segesser LK, Jegger D, Mucciolo G, Tozzi P, Mucciolo A, Delay D, Mallabiabarrena I, Horisberger J. The Smart Canula™: A new tool for remote access in limited access cardiac surgery. *Heart Surg Forum* 2005;8:E241-E245
- 7) MuellerXM, Mallabiabarrena I, Mucciolo G, von Segesser LK. Optimized venous return with a self-expanding cannula: from computational fluid dynamics to clinical application. *Interactive CardioVascular and Thoracic Surgery* 2002; 1: 23-27
- 8) Jegger D, Corno AF, Mucciolo A, Mucciolo G, Boone Y, Horisberger J, Seigneul I, Jachertz M, von Segesser LK. A prototype paediatric venous cannula with shape change in situ. *Perfusion* 2003; 18: 61-65
- 9) Mueller XM, Tevaearai HT, Jegger D, Horisberger J, Mucciolo G, von Segesser LK. A new expandable venous cannula for minimal access heart surgery. *Ann Thorac Surg* 2002; 74; S1330-1333
- 10) Jegger D, Chassot PG, Bernath MA, Horisberger J, Gersbach P, Tozzi P, Delay D, von Segesser LK. A novel technique using echocardiography to evaluate venous cannula performance perioperatively in CPB cardiac surgery. *Eur J Cardio-thorac Surg* 2006; 29: 525-529
- 11) Delay D, Lardi C, Jaussi A, von Segesser LK. Hepato-atrial anastomosis, "the other Senning operation" for treatment of Budd-Chiari syndrome. *Swiss Med Wkly* 2005;135:235-237
- 12) Corno AF, Horisberger J, Jegger D, von Segesser LK. Right atrial surgery with un-snared inferior vena cava. *European Journal for Cardio-thoracic Surgery* 2004; 26: 219-20